
Neural Correlates of Refixation Saccades and Antisaccades in Normal and Schizophrenia Subjects

Jennifer E. McDowell, Gregory G. Brown, Martin Paulus, Antígona Martínez, Sara E. Stewart, David J. Dubowitz, and David L. Braff

Background: *Schizophrenia subjects demonstrate difficulties on tasks requiring saccadic inhibition, despite normal refixation saccade performance. Saccadic inhibition is ostensibly mediated via prefrontal cortex and associated cortical/subcortical circuitry. The current study tests hypotheses about the neural substrates of normal and abnormal saccadic performance among subjects with schizophrenia.*

Methods: *Using functional magnetic resonance imaging, blood oxygenation level-dependent (BOLD) data were recorded while 13 normal and 14 schizophrenia subjects were engaged in refixation and antisaccade tasks.*

Results: *Schizophrenia subjects did not demonstrate the increased prefrontal cortex BOLD contrast during antisaccade performance that was apparent in the normal subjects. Schizophrenia subjects did, however, demonstrate normal BOLD contrast associated with refixation saccade performance in the frontal and supplementary eye fields, and posterior parietal cortex.*

Conclusions: *Results from the current study support hypotheses of dysfunctional prefrontal cortex circuitry among schizophrenia subjects. Furthermore, this abnormality existed despite normal BOLD contrast observed during refixation saccade generation in the schizophrenia group.* Biol Psychiatry 2002;51:216–223 © 2002 Society of Biological Psychiatry

Key Words: Saccades, antisaccades, schizophrenia, fMRI, prefrontal cortex

Introduction

Frontal cortex dysfunction is hypothesized to be a critically important deficit in schizophrenia (Berman et al 1992; Buchsbaum et al 1992). Among the numerous behaviors supported by frontal cortex and associated

cortical/subcortical circuitry are saccadic eye movements. Saccades exist in a hierarchy of increasingly complex behavior (Leigh and Zee 1991, p. 79). With each step up in the hierarchy, the basic neural circuitry is conserved but additional, primarily cortical, regions are recruited. For the purposes of the current manuscript, the most basic level of saccadic performance consists of visually guided refixation saccades, movements that rapidly redirect the gaze to a visual target. At a more cognitively complex level are antisaccades, movements that redirect gaze to the *mirror image* location (opposite direction, same amplitude) of a visual cue. An initial glance *toward* the cue constitutes an antisaccade error.

The characteristics of saccadic performance among schizophrenia subjects have been extensively evaluated. Simple refixation saccade performance among schizophrenia subjects does not differ from that of normal subjects (Crawford et al 1998; Fukushima et al 1990; Iacono et al 1981; McDowell et al 1996), with the possible exception of specific medication-induced effects (Sweeney et al 1997). This finding suggests that the neural substrates underlying the basic saccade-generating mechanisms are functionally intact among schizophrenia subjects.

Schizophrenia subjects' performance, however, differs from that of normal subjects during antisaccade tasks. Schizophrenia subjects generate an increased proportion of antisaccade errors toward a cue (Crawford et al 1995; Fukushima et al 1990; Katsanis et al 1997; McDowell and Clementz 1997; Sereno and Holzman 1995). The first-degree, nonpsychotic relatives of schizophrenia subjects also generate an increased proportion of antisaccade errors (Crawford et al 1998; Katsanis et al 1997; McDowell et al 1999; Ross et al 1998).

The neural circuitry supporting refixation and antisaccade performance is relatively well understood. Thus, hypotheses can be generated regarding the neural bases of both normal and abnormal saccadic performance. In this study, functional magnetic resonance imaging (fMRI) was used to test hypotheses about the neural substrates of normal and abnormal saccadic performance among subjects with schizophrenia.

From the University of California, San Diego, Department of Psychiatry (JEM, GGB, MP, SES, DLB); and Veterans Affairs, San Diego Healthcare System (GGB, MP), San Diego, California; Cornell University, Sackler Institute of Weill Medical College, New York, New York (AM); and California Institute of Technology, Division of Biology, Pasadena, California (DJD).

Address correspondence to Jennifer E. McDowell, Ph.D., UCSD, Department of Psychiatry 0804, 9500 Gilman Drive, La Jolla CA 92093-0804.

Received February 2, 2001; revised May 21, 2001; accepted June 1, 2001.

The first hypothesis addressed here is that both schizophrenia and normal subjects will demonstrate increased and similar signal contrast in cortical regions known to support refixation saccade performance. As determined from both human and nonhuman primate studies, (Everling and Munoz 2000; Leigh and Zee 1991; Tehovnik et al 2000) those regions include frontal eye fields (FEF), supplementary eye fields (SEF) and posterior parietal cortex (PPC). Results from existing imaging studies in normal subjects consistently show increased signal contrast in these three reciprocally connected cortical regions during saccade performance (Anderson et al 1994; Bodis-Wollner et al 1997; Darby et al 1996; Fox et al 1985; Grosbas et al 1999; Kawashima et al 1996; Law et al 1997; Luna et al 1998; Melamed and Larsen 1979; O'Driscoll et al 1998; Petit et al 1996; Sweeney et al 1996).

The second hypothesis is that normal, but not schizophrenia subjects, will show increased prefrontal cortex signal contrast associated with antisaccade performance. Patients with lesions in the dorsolateral prefrontal cortex (DLPFC), but not those with lesions of FEF (Gaymard et al 1999) or other cortical regions (Pierrot-Deseilligny 1994) make significantly more antisaccade errors toward a cue. Imaging studies of antisaccade performance are not as numerous as those of refixation performance and report more varied results. O'Driscoll et al (1995) and Paus et al (1993) showed no prefrontal blood flow differences between refixation and antisaccade performance using positron emission tomography (PET) techniques. Conversely, Sweeney et al (1996) observed a bilateral DLPFC signal associated with antisaccade performance in normal subjects, a finding that has been replicated in PET (Doricchi et al 1997) and fMRI (Müri et al 1998).

In general, there is a less extensive literature describing functional neuroimaging data in schizophrenia subjects performing antisaccade tasks. Crawford et al (1996) reported no blood flow difference (assessed by single-photon emission tomography [SPET]) in DLPFC during antisaccades when comparing a group of poorly performing schizophrenia subjects to a group of normally performing schizophrenia subjects. Nakashima et al (1994), however, reported increased blood flow (measured with PET) in left DLPFC in normal, but not schizophrenia, subjects during a task that was similar to an antisaccade task in its requirement to look opposite of a visual target.

In order to test hypotheses one and two, however, potential artifacts must be considered before drawing inferences regarding signal changes representative of neuronal activity. One persistent potential confound between groups in neuroimaging studies using psychiatric subjects is the extent of head movement. After using a strategy to quantify and correct both non-stimulus- and stimulus-correlated head movement during imaging, blood oxygen-

ation level-dependent (BOLD) signal contrast was evaluated during refixation and antisaccade performance. Refixation saccades provide an excellent baseline condition for antisaccade comparison, because the same circuitry is hypothesized to subservise each behavior, with the exception of additional prefrontally mediated inhibition necessary for correct antisaccade performance. The current study directly compares refixation and antisaccade performance within a single run.

Methods and Materials

Subjects

Sixteen DSM-III-R schizophrenia (mean age = 37 years; SD = 8; 19% female; mean years of education = 13.8) and 14 normal (mean age = 35 years, SD = 9; 7% female; mean years of education = 14.7) subjects were imaged while performing saccadic tasks. All participants were in good physical health, absent of neurological hard signs, free from current psychoactive substance use disorders, and were screened for claustrophobia, potential pregnancy, bodily shrapnel or other metals, pacemakers, aortic clips or heart valves, implanted prosthesis, and colorblindness. After complete description of the study to the subjects, written informed consent was obtained.

Subjects with chronic schizophrenia were recruited from local outpatient services and diagnosed using the Structured Clinical Interview for DSM-III-R Axis I Disorders (Spitzer et al 1990). Ninety-three percent of the schizophrenia subjects were taking various doses of antipsychotic (29% on typical, 64% on atypical) and anticholinergic (21%) medication.

Normal subjects were recruited through advertisements posted on community bulletin boards and screened for a personal and family history (first-degree relatives) of psychiatric disorders. As determined by self-report, only subjects without an Axis I disorder, family history of psychotic disorder, suicide, or psychiatric hospitalization were asked to continue with the imaging procedure.

Imaging Procedure

Subjects began by spending 5 min in a mock scanner environment for desensitization to the confined space and loud noise, and to provide a standardized pre-exposure period. Subjects were then transferred to a Siemens (Erlangen, Germany) Vision 1.5 scanner. Cushioning inside the head coil was adjusted for optimal positioning of the subject's head, and restraints were placed over the forehead and chin.

Automatic shimming was completed and midsagittal localizer images were acquired to optimize head position in the coil so that the entire supratentorial cortex could be imaged. Functional scans consisted of 32 axial contiguous, gradient-recalled echo-planar images (4 mm thick, repetition time [TR] = 3 sec, echo time [TE] = 40 msec, flip angle = 90 degrees, field of vision [FOV] = 220 mm, 3.4 × 3.4 mm in plane resolution) that were acquired in the axial plane while subjects were engaged in eye movement tasks. High-resolution structural images were ac-

quired using a three-dimensional MPRAGE (magnetization prepared rapid gradient echo) protocol (TR = 11.4 sec, TE = 4.4 msec, flip angle = 10 degrees, FOV = 256 mm, 1 mm isotropic resolution) across a 128-mm axial slab.

Stimulus Presentation

Colored asterisks were rear projected (Proxima Corp., Wilsonville, OR) onto a screen that the subject viewed through a mirror. One and only one stimulus was present at a time, either at the central position or approximately 7 degrees right or left of center. Each 5½-min run consisted of alternating blocks of 30-sec conditions. Every block of saccade stimuli contained an equal number of trials randomly distributed to either side. Subjects were quizzed using practice stimuli. Technical limitations prevented recording eye movement performance inside the scanner. Seven pilot subjects, however, performed trials while their eye position was observed and videotaped. Although the exact metrics of eye movement could not be recorded, the accuracy and attentiveness of the subjects could be monitored, and all subjects demonstrated task appropriate eye movements. Additionally, antisaccade performance was quantified for a subset of subjects outside of the scanner (see Behavioral Methods below).

REFIXATION SACCAD E STUDY. Subjects alternated between blocks of fixation (30 sec of central target presentation) and refixation stimuli (12 trials of 1 sec of central target presentation followed by presentation of the peripheral target for 1.5 sec), beginning and ending with fixation blocks. Subjects were instructed to keep their eyes on the target when it was centrally located, and to move their eyes as quickly and accurately as possible to the peripheral target when it appeared.

ANTISACCAD E STUDY. Subjects alternated between blocks of refixation stimuli (same as above) and antisaccade stimuli (10 trials of 1.5 sec of central target presentation followed by presentation of the peripheral target for 1.5 sec), beginning and ending with refixation blocks. A change in the target color indicated a switch in task from refixation (green) to antisaccades (red). When the target was green, subjects were instructed to move their eyes as quickly and accurately as possible to the target each time it moved to the periphery. When the target was red, subjects were instructed to look as quickly and accurately as possible to the *mirror image* (opposite direction, same amplitude) of the peripheral cue.

Behavioral Methods

Antisaccade performance was recorded outside of the magnet for a subset of subjects (normal $n = 8$, schizophrenia $n = 10$). Horizontal eye movements were measured using an Eye Trac Model 210 monitor (Applied Science Laboratories, Bedford, MA) and infrared spectacles mounted on eyeglass frames. Eye movement recordings were digitized at 256 Hz using an A-to-D board connected to an IBM-compatible computer and recorded to hard disk for offline scoring. Performance was simultaneously monitored by the experimenter.

Prior to the task, subjects were given initial calibration trials

followed by task instructions. Fifty antisaccade trials were presented. The trials had the same stimulus characteristics as those presented in the magnet (target presented for 1.5 sec centrally followed by 1.5 sec at 7 degrees right or left of center). Data were scored using programs written in Matlab (The Mathworks Inc., Natick, MA) for the express purpose of evaluating saccade direction. An initial glance *toward* the cue constituted an antisaccade error.

Analysis

IMAGE PREPARATION AND REGISTRATION. Analysis was conducted using analysis of functional neuroimages (AFNI) (Cox 1996). Three-dimensional volumetric registration (using a weighted least squares) was used to align brain volumes across the time series of images. The most centrally located volume, that is the volume whose position was most characteristic of the series, was used as a base for correction of minor movements between consecutively acquired images (Cox and Jesmanowicz 1999). Furthermore, the parameters derived by this procedure characterize the amount of head movement in translational (measured in mm) and rotational (measured in degrees) space (Bullmore et al 1999) with increased magnitude of these values reflecting increased movement. To evaluate non-stimulus-correlated movement, changes in translational and rotational space were calculated as the mean Euclidean distance change from zero for each subject. To evaluate stimulus-correlated movement, the motion parameters for each individual subject were correlated with the reference function (see below for characteristics of the reference function). Upon visual inspection of the distribution of non-stimulus- and stimulus-correlated motion, subjects who were clear outliers were eliminated from further analysis.

IMAGE ANALYSIS. On a subject by subject basis, the BOLD signal intensities across time were cross-correlated with a series of phase-shifted trapezoid reference functions and corrected for linear drift. The trapezoid function was a modified square-wave, in which the time of baseline stimulus presentation was represented by zeros and the time of experimental stimulus presentation was represented by ones, with 6-sec (equivalent to 2 TRs) rise and fall periods between conditions. The motion parameters were used as regressors to partial out the variance due to movement across time.

Following the cross-correlation analysis, each subject's data were transformed into standardized space (based on the Talairach and Tournoux Atlas, 1988) and resampled to $3 \times 3 \times 3$ mm voxels. A full-width, half-maximum isotropic Gaussian blur equivalent of 1 voxel size was applied to the data. The group data were then submitted to random effects t tests for within- (versus zero) and between-groups on a voxel by voxel basis, resulting in t maps. In an effort to identify only neuronally meaningful BOLD signal changes and to preserve an alpha level of $p = 0.05$, only areas that were part of a cluster of contiguous voxels with a t value of .025 and exceeded a volume of $377 \mu\text{L}$ (equivalent of 13 voxels) were accepted for final analysis. Figures are presented as η^2 effect size maps (Cohen 1973).

Results

Behavioral Analysis

When recorded on antisaccade tasks outside of the magnet, significantly fewer correct trials (correct trials/total trials) were generated by schizophrenia (mean = .59, SD = .20) than normal subjects [mean = .93, SD = .04; $F(1,16) = 23.37$, $p \leq .0002$; Figure 1].

Movement Analysis

NON-STIMULUS-CORRELATED MOTION. The distribution of change in rotational space from zero is illustrated in Figure 2. It is evident from the data that most subjects have relatively little change in rotational position over the course of a 5½-min scanning session. The exceptions are two clear outliers, one from each group (normal #1, schizophrenia #1). The Euclidean distance distributions were similar for translational space.

STIMULUS-CORRELATED MOTION. The distribution of change in rotational space demonstrates that the corre-

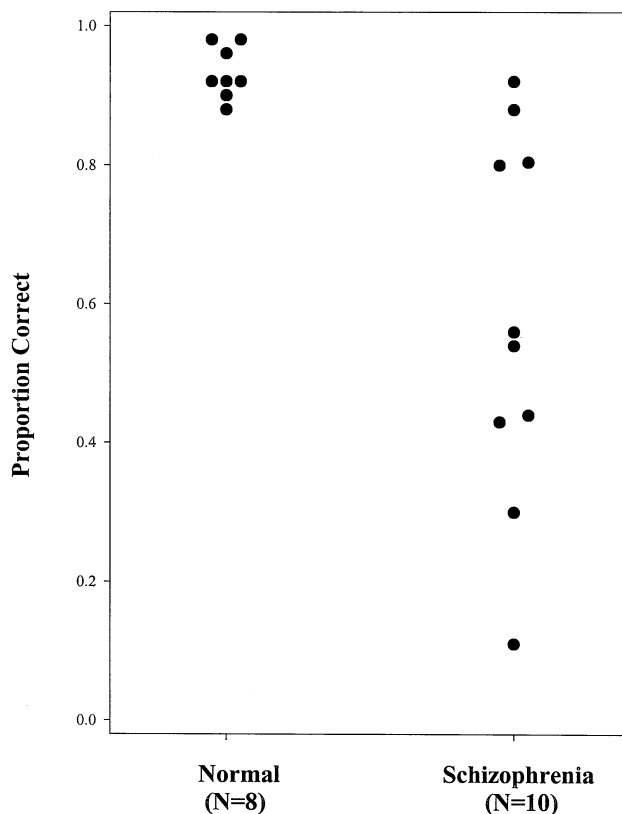


Figure 1. Mean proportion of correct antisaccade responses for normal ($n = 8$) and schizophrenia ($n = 10$) subjects (data recorded outside of the magnet). Zero indicates an error generated toward the cue on every trial. One indicates correct performance to the mirror image location on every trial.

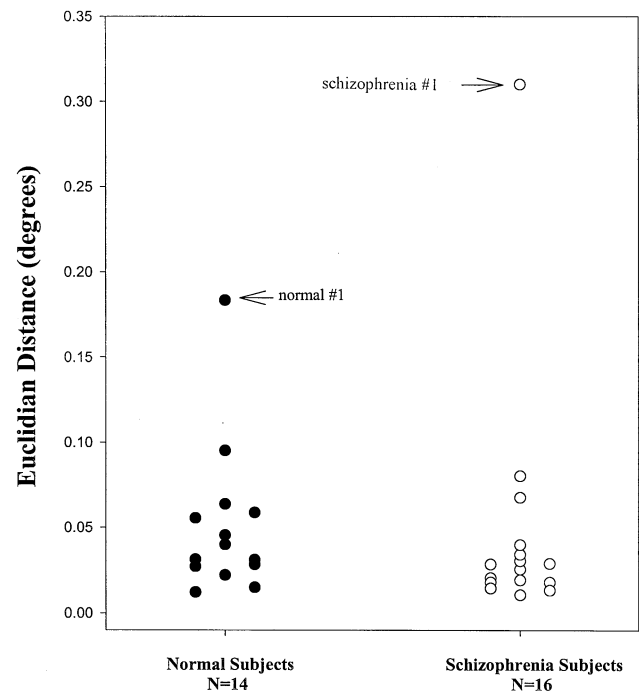


Figure 2. The Euclidean distance (the square root of the sum of squares of the head displacement in each plane) was used to determine the amount of change from zero (measured in degrees) in the rotational plane. The normal subjects ($n = 14$) are shown as solid circles, the schizophrenia subjects ($n = 16$) are shown as hollow circles. One subject from each group lies clearly outside the distributions.

lation between the reference wave and the three rotational planes are small, with the exception of two points that are outliers compared with the rest of the distribution (Figure 3). The two extreme points occur in the planes characterizing roll and pitch, and each represents data from the same subject (schizophrenia #2). The stimulus-correlated movement was similar for translational space.

SUMMARY OF MOVEMENT ANALYSIS. The three subjects who were clear outliers on the movement parameters were excluded from further analysis, resulting in similar group distributions for non-stimulus-correlated and stimulus-correlated movement variables. This reduced the probability that apparent signal (either within or between groups) in the following analysis is due to movement artifact.

Image Analysis

The remaining 13 normal and 14 schizophrenia subjects contributed to the group data analyzed for BOLD signal change associated with refixation (fixation baseline) and antisaccades (refixation saccade baseline). Reports of BOLD signal changes are limited to those areas identified

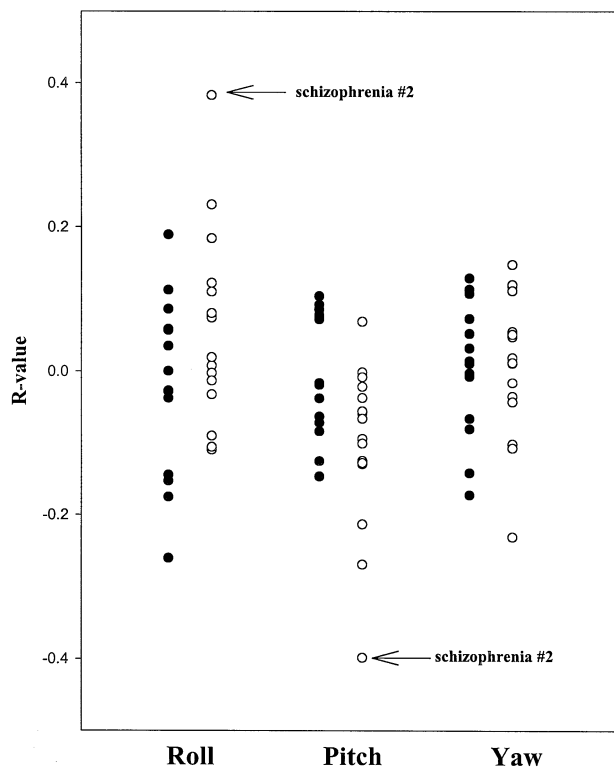


Figure 3. The y axis shows the r -value resulting from the correlation between the reference wave and a motion parameter characterizing three directions of rotational movement: roll, pitch, or yaw. The normal subjects ($n = 14$) are shown in dark, the schizophrenia subjects ($n = 16$) are shown in white. Thus, each subject contributes three points to the graph—the value characterizing head motion in each of the three potential directions. Two points have an r value of $\geq .25$. Both data points are contributed by schizophrenia subject #2.

a priori as regions involved in saccade generation: FEF, SEF, PPC, and DLPFC (Talairach coordinates are designated using center of mass for the normal subjects).

REFIXATION SACCADE STUDY. T tests comparing refixation saccade-associated BOLD signal change for each group versus zero were calculated. Normal and schizophrenia groups showed similar BOLD contrast in frontal eye fields (Talairach coordinates; $x \pm 41$, $y = -2$, $z = 47$) and supplementary eye fields (Talairach coordinates; $x = -3$, $y = -1$, $z = 60$), and also parietal cortex (Talairach coordinates; $x \pm 17$, $y = -67$, $z = 56$; Figure 4a and 4b). The between-group η^2 effect size t map demonstrated that there were no significant differences in this plane in these areas (Figure 4c).

ANTISACCADE STUDY. Both within- and between-group t tests showed that normal, but not schizophrenia, subjects demonstrated increased BOLD contrast in the DLPFC (Talairach coordinates; $x = 23$, $y = 42$, $z = 36$)

lateralized to the right hemisphere. This pattern is clearly demonstrated in the within- (Figures 5A and 5B) and between-group (Figures 5C and 5D) η^2 effect size t map.

Discussion

The current study evaluated the BOLD contrast associated with refixation and antisaccade performance in normal and schizophrenia subjects. Schizophrenia subjects did not demonstrate the increased prefrontal cortex BOLD contrast during antisaccade performance that was apparent in the normal subjects. In the subset of subjects tested outside of the magnet, schizophrenia subjects also generated an increased proportion of antisaccade errors, consistent with previous results (Crawford et al 1995; Fukushima et al 1990; Katsanis et al 1997; McDowell and Clementz 1997; Sereno and Holzman 1995). These data are consistent with extant hypotheses that prefrontal cortex and its associated cortical and subcortical circuitry must be functionally intact for correct antisaccade performance and may be disrupted in schizophrenia.

Evidence suggests that DLPFC and its circuitry support numerous and varied behaviors (for example, see Goldman-Rakic 1987). Two elements necessary for correct antisaccade performance that are hypothesized to be mediated by DLPFC are inhibition of the initial saccade and maintenance of the spatial location of a correct response. Problems with either element may result in poor antisaccade performance, although they may be manifest in different ways. It appears that the role of DLPFC in regulating saccadic inhibition is the most parsimonious explanation for the observed results. First is the temporal sequence of events. The initial glance must be inhibited before a saccade is generated to a spatial location. Second is that the instructions require a movement away from the cue as quickly as possible, minimizing the time necessary to maintain a spatial location. Third, although schizophrenia subjects are often not as accurate on correct antisaccade trials, the between-groups differences are often greater for antisaccade error rate than for antisaccade accuracy (Crawford et al 1995; McDowell and Clementz 1997). Fourth and finally, increased antisaccade errors are only one of a series of abnormalities during volitional saccade tasks that could be characterized as a problem with saccadic inhibition (for a review, see Clementz 1998). Briefly, schizophrenia patients generate more of the very fast reaction time saccades known as express saccades (Clementz 1996; Matsue et al 1994), have faster latencies during predictive saccades (Karoumi et al 1998; McDowell et al 1996), and make more saccades during the delay period of ocular motor delayed response tasks (Everling et al 1996; McDowell et al 2001; McDowell and Clementz 1996) than normal subjects.

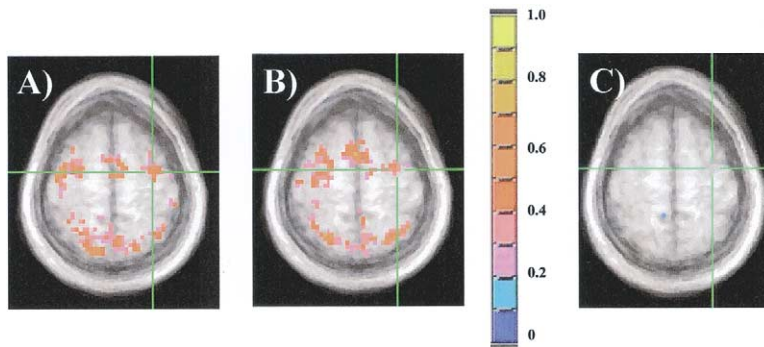


Figure 4. Axial views of η^2 effect size maps for blood oxygenation level-dependent contrast associated with refixation saccade performance for (A) normal subjects, (B) schizophrenia subjects, and (C) the between-group t test. The color scale identifies the η^2 effect size from 0 to 1 sigma. The green crosshairs mark the same frontal eye field location in each plane. The effect size maps are overlaid on an average structural map of 14 normal subjects. Figures are shown using radiological convention (left hemisphere on right side).

Results from the current study suggest that schizophrenia subjects may manifest prefrontally mediated saccadic inhibition problems. Perhaps prefrontal neurons do not activate as strongly in schizophrenia subjects, or it may be that there is a timing problem that decreases the probability that inhibition occurs. Importantly, the decreased prefrontal signal existed even though the brain response in FEF, SEF, and PPC was normal during refixation and antisaccade generation in the schizophrenia group.

In the normal subjects, prefrontal BOLD signal contrast associated with antisaccade performance was lateralized to the right hemisphere. Schizophrenia subjects did not show increased BOLD signal contrast in the region. Although some studies have not found evidence of prefrontal cortex activation associated with antisaccades (O'Driscoll et al 1995; Paus et al 1993), other studies have reported bilateral (Doricchi et al 1997; Sweeney et al 1996) and unilateral (Nakashima et al 1994) signal contrast in prefrontal cortex of normal subjects. The unilateral increase in BOLD signal in the current report may reflect right hemisphere dominance for visual and motor hemi-attention. For instance, visual neglect is caused almost exclusively by right hemisphere lesions (Mesulam 1999). Additionally, recent imaging studies demonstrate that inhibition

of a prepotent motor response may lateralize to the right hemisphere (de Zubicar et al 2000; Garavan et al 1999).

Despite the evidence provided here for disrupted DLPFC functioning among schizophrenia subjects, alternative hypotheses should be considered. First, group differences in head motion could result in a decreased ability either to resolve signal above the noise or result in artifactual signal. In this study, however, an attempt was made to maintain the quality of data between groups by evaluating head motion and eliminating extreme outliers on movement parameters. As a result, the probability was reduced that the group means were either devalued by non-stimulus-correlated movement or accentuated by stimulus-correlated movement. Second, given the characteristics of the alternating refixation/antisaccade paradigm, it is possible that the schizophrenia subjects never learned to make the switch to antisaccades when the color changed. This possibility was minimized by screening out colorblind subjects. Subjects also were cooperative, received and repeated verbal instructions about task requirements, and were given practice trials in which they reported the direction of correct responses when presented with test stimuli.

Future studies will incorporate measurement of eye movement metrics while subjects are in the scanner.

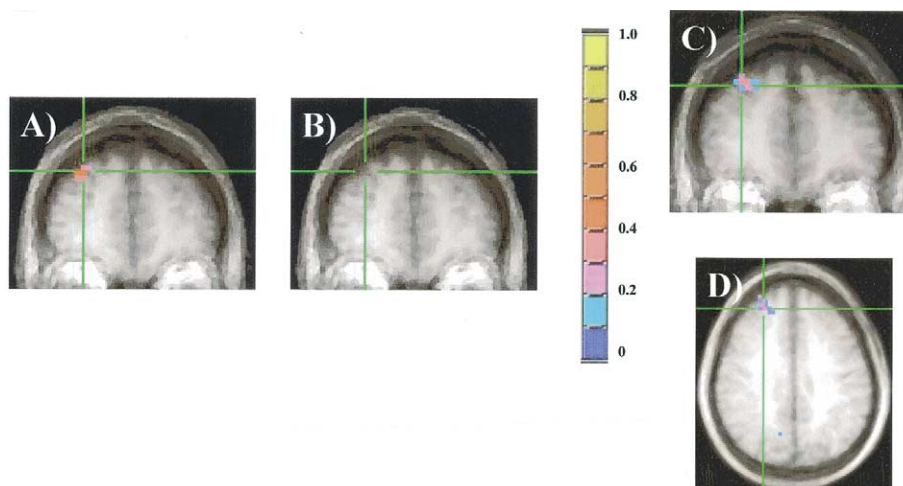


Figure 5. Coronal views of η^2 effect size maps for blood oxygenation level-dependent (BOLD) contrast associated with antisaccade performance for (A) normal subjects and (B) schizophrenia subjects. The between-group t test maps for BOLD contrast associated with antisaccade performance are shown in (C) coronal and (D) axial orientations. The color scale identifies the effect size from 0 to 1 sigma. The green crosshairs mark the same dorsolateral prefrontal cortex location in each plane. Figures are shown radiologically oriented.

Although not measured for all subjects during the fMRI study, pilot observations of eye position agreed with those measured out of the scanner. In the subset of subjects recorded on antisaccade performance outside the magnet, eight of eight normal subjects scored better than 85% correct. Six of 10 schizophrenia subjects, however, performed below 60% correct. All subjects self-corrected before they were cued to do so on the majority of error trials. These distributions are consistent with other reports of antisaccade performance from our laboratory (McDowell and Clementz 1997).

The current study provides corroborating evidence that prefrontally mediated inhibition is functionally impaired among schizophrenia subjects. Importantly, the impairment is not of a global nature, because it occurs in conjunction with normal patterns of neural activity associated with saccade generation. Behaviorally, the increased proportion of saccadic errors demonstrated by schizophrenia subjects is observed among the nonpsychotic relatives of schizophrenia subjects. Therefore, biological relatives of schizophrenia subjects provide a group in which further imaging studies of prefrontal cortex and its associated circuitry may be evaluated. Similar patterns of functional activity during antisaccade performance in schizophrenia subjects and their biological relatives would provide increased confidence that prefrontal cortex circuitry dysfunction was a necessary, although not sufficient, part of a liability for developing the illness.

Preparation of the manuscript was supported by MH18399 (Fellowship: Clinical Psychopharmacology and Psychobiology), NARSAD (Young Investigator Award) and VISN 22 Mental Illness, Research, and Education Center, and MH4228.

We thank R. Buxton and E. Wong for the technical expertise that made the study possible, and the subjects who generously agreed to participate.

References

- Anderson TJ, Jenkins IH, Brooks DJ, Hawken MB, Frackowiak RS, Kennard C (1994): Cortical control of saccades and fixation in man. A PET study. *Brain* 117:1073–1084.
- Berman KF, Torrey EF, Daniel DG, Weinberger DR (1992): Regional cerebral blood flow in monozygotic twins discordant and concordant for schizophrenia. *Arch Gen Psychiatry* 49:927–934.
- Bodis-Wollner I, Bucher SF, Seelos KC, Paulus W, Reiser M, Oertel WH (1997): Functional MRI mapping of occipital and frontal cortical activity during voluntary and imagined saccades. *Neurology* 49:416–420.
- Buchsbaum MS, Haier RJ, Potkin SG, Nuechterlein K, Bracha HS, Katz M, et al (1992): Frontostriatal disorder of cerebral metabolism in never-medicated schizophrenics. *Arch Gen Psychiatry* 49:935–942.
- Bullmore ET, Brammer MJ, Rabe-Hesketh S, et al (1999): motion in generic brain activation studies using fMRI. *Hum Brain Mapp* 7:38–48.
- Clementz BA (1996): The ability to produce express saccades as a function of gap interval among schizophrenia patients. *Exp Brain Res* 111:121–130.
- Clementz BA (1998): Psychophysiological measures of (dis)inhibition as liability indicators for schizophrenia. *Psychophysiology* 35:648–668.
- Cohen J (1973): Eta-squared and partial eta-squared in fixed factor and ANOVA designs. *Educational Psychological Measurement* 33:107–112.
- Cox RW (1996): AFNI: Software for analysis and visualization of functional magnetic resonance neuroimages. *Comput Biomed Res* 29:162–173.
- Cox RW, Jesmanowicz A (1999): Real-time 3D image registration for functional MRI. *Magn Reson Med* 42:1014–1018.
- Crawford TJ, Haeger B, Kennard C, Reveley MA, Henderson L (1995): Saccadic abnormalities in psychotic patients. I. Neuroleptic-free psychotic patients. *Psychol Med* 25:461–471.
- Crawford TJ, Puri BK, Nijran KS, Jones B, Kennard C, Lewis SW (1996): Abnormal saccadic distractibility in patients with schizophrenia: a 99mTc-HMPAO SPET study. *Psychol Med* 26:265–277.
- Crawford TJ, Sharma T, Puri BK, Murray RM, Berridge DM, Lewis SW (1998): Saccadic eye movements in families multiply affected with schizophrenia: The Maudsley Family Study. *Am J Psychiatry* 155:1703–1710.
- Darby DG, Nobre AC, Thangaraj V, Edelman R, Mesulam MM, Warach S (1996): Cortical activation in the human brain during lateral saccades using EPSTAR functional magnetic resonance imaging. *Neuroimage* 3:53–62.
- de Zubicaray GI, Andrew C, Zelaya FO, Williams SC, Dumanoir C (2000): Motor response suppression and the prepotent tendency to respond: a parametric fMRI study. *Neuropsychologia* 38:1280–1291.
- Doricchi F, Perani D, Incoccia C, Grassi F, Cappa SF, Bettinardi V, et al (1997): Neural control of fast-regular saccades and antisaccades: an investigation using positron emission tomography. *Exp Brain Res* 116:50–62.
- Everling S, Krappmann P, Preuss S, Brand A, Flohr H (1996): Hypometric primary saccades of schizophrenics in a delayed-response task. *Exp Brain Res* 111:289–296.
- Everling S, Munoz DP (2000): Neuronal correlates for preparatory set associated with pro-saccades and anti-saccades in the primate frontal eye field. *J Neurosci* 20:387–400.
- Fox PT, Fox JM, Raichle ME, Burde RM (1985): The role of cerebral cortex in the generation of voluntary saccades: a positron emission tomographic study. *J Neurophysiol* 54:348–369.
- Fukushima J, Fukushima K, Morita N, Yamashita I (1990): Further analysis of the control of voluntary saccadic eye movements in schizophrenic patients. *Biol Psychiatry* 28:943–958.
- Garavan H, Ross TJ, Stein EA (1999): Right hemispheric dominance of inhibitory control: An event-related functional MRI study. *Proc Natl Acad Sci USA* 96:8301–8306.
- Gaymard B, Ploner CJ, Rivaud-Péchéux S, Pierrot-Deseilligny C (1999): The frontal eye field is involved in spatial short-term memory but not in reflexive saccade inhibition. *Exp Brain Res* 129:288–301.

- Goldman-Rakic PS (1987): Circuitry of primate prefrontal cortex and regulation of behavior by representational memory. In: Plum F, Mountcastle V (eds). *Handbook of Physiology: Section I: The Nervous System*, vol 5. American Physiological Society, Bethesda, MD 373–417.
- Grosbras MH, Lobel E, Van de Moortele PF, LeBihan D, Berthoz A (1999): An anatomical landmark for the supplementary eye fields in human revealed with functional magnetic resonance imaging. *Cereb Cortex* 9:705–711.
- Iacono WG, Tuason VB, Johnson RA (1981): Dissociation of smooth-pursuit and saccadic eye tracking in remitted schizophrenics. An ocular reaction time task that schizophrenic perform well. *Arch Gen Psychiatry* 38:991–996.
- Karoumi B, Ventre-Dominey J, Dalery J (1998): Predictive saccade behavior is enhanced in schizophrenia. *Cognition* 68:B81–B91.
- Katsanis J, Kortenkamp S, Iacono WG, Grove WM (1997): Antisaccade performance in patients with schizophrenia and affective disorder. *J Abnorm Psychol* 106:468–472.
- Kawashima R, Naitoh E, Matsumura M, Itoh H, Ono S, Satoh K, et al (1996): Topographic representation in human intraparietal sulcus of reaching and saccade. *Neuroreport* 7:1253–1256.
- Law I, Svarer C, Holm S, Paulson OB (1997): The activation pattern in normal humans during suppression, imagination and performance of saccadic eye movements. *Acta Physiol Scand* 161:419–434.
- Leigh RJ, Zee DS (1991): *The Neurology of Eye Movements*, 2nd ed. Philadelphia: F.A. Davis.
- Luna B, Thulborn KR, Strojwas MH, McCurtain BJ, Berman RA, Genovese CR, et al (1998): Dorsal cortical regions subserving visually guided saccades in humans: an fMRI study. *Cereb Cortex* 8:40–47.
- Matsue Y, Osakabe K, Saito H, Goto Y, Ueno T, Matsuoka H, et al (1994): Smooth pursuit eye movements and express saccades in schizophrenic patients. *Schizophr Res* 12:121–130.
- McDowell JE, Brenner CA, Myles-Worsley M, Coon H, Byerley W, Clementz BA (2001): Ocular motor delayed-response task performance among schizophrenia patients and their biological relatives. *Psychophysiology* 38:153–156.
- McDowell JE, Clementz BA (1996): Ocular-motor delayed-response task performance among schizophrenia patients. *Neuropsychobiology* 34:67–71.
- McDowell JE, Clementz BA (1997): The effect of fixation condition manipulations on antisaccade performance in schizophrenia: Studies of diagnostic specificity. *Exp Brain Res* 115:333–344.
- McDowell JE, Clementz BA, Wixted JT (1996): Timing and amplitude of saccades during predictive saccadic tracking in schizophrenia. *Psychophysiology* 33:93–101.
- McDowell JE, Myles-Worsley M, Coon H, Byerley W, Clementz BA (1999): Measuring liability for schizophrenia using optimized antisaccade stimulus parameters. *Psychophysiology* 36:138–141.
- Melamed E, Larsen B (1979): Cortical activation pattern during saccadic eye movements in humans: Localization by focal cerebral blood flow increases. *Ann Neurol* 5:79–88.
- Mesulam MM (1999): Spatial attention and neglect: Parietal, frontal and cingulate contributions to the mental representation and attentional targeting of salient extrapersonal events. *Philos Trans R Soc Lond B Biol Sci* 354:1325–1346.
- Müri RM, Heid O, NirKKO AC, Ozdoba C, Felblinger J, Schroth G, et al (1998): Functional organisation of saccades and antisaccades in the frontal lobe in humans: a study with echo planar functional magnetic resonance imaging. *J Neurol Neurosurg Psychiatry* 65:374–377.
- Nakashima Y, Momose T, Sano I, Katayama S, Nakajima T, Niwa S, et al (1994): Cortical control of saccade in normal and schizophrenic subjects: A PET study using a task-evoked rCBF paradigm. *Schizophr Res* 12:259–264.
- O'Driscoll GA, Alpert NM, Matthyse SW, Levy DL, Rauch SL, Holzman PS (1995): Functional neuroanatomy of antisaccade eye movements investigated with positron emission tomography. *Proc Natl Acad Sci USA* 92:925–929.
- O'Driscoll GA, Strakowski SM, Alpert NM, Matthyse SW, Rauch SL, Levy DL, et al (1998): Differences in cerebral activation during smooth pursuit and saccadic eye movements using positron-emission tomography. *Biol Psychiatry* 44:685–689.
- Paus T, Petrides M, Evans AC, Meyer E (1993): Role of the human anterior cingulate cortex in the control of oculomotor, manual, and speech responses: A positron emission tomography study. *J Neurophysiol* 70:453–469.
- Petit L, Orssaud C, Tzourio N, Crivello F, Berthoz A, Mazoyer B (1996): Functional anatomy of a prelearned sequence of horizontal saccades in humans. *J Neurosci* 16:3714–3726.
- Pierrot-Deseilligny C (1994): Saccade and smooth pursuit impairment after cerebral hemispheric lesions. *Eur Neurol* 34:121–134.
- Ross RG, Harris JG, Olincy A, Radant A, Adler LE, Freedman R (1998): Familial transmission of two independent saccadic abnormalities in schizophrenia. *Schizophr Res* 30:59–70.
- Sereno AB, Holzman PS (1995): Antisaccades and smooth pursuit eye movements in schizophrenia. *Biol Psychiatry* 37:394–401.
- Spitzer RI, Williams JBW, Gibbon M, First MB (1990): *Structured Clinical Interview for DSM III-R-Patient Version 1.0 (SLID-P)*. Washington, D.C., American Psychiatric Press.
- Sweeney JA, Bauer KS, Keshavan MS, Haas GL, Schooler NR, Kroboth PD (1997): Adverse effects of risperidone on eye movement activity: A comparison of risperidone and haloperidol in antipsychotic-naïve schizophrenic patients. *Neuropsychopharmacology* 16:217–228.
- Sweeney JA, Mintun MA, Kwee S, Wiseman MB, Brown DL, Rosenberg DR, et al (1996): Positron emission tomography study of voluntary saccadic eye movements and spatial working memory. *J Neurophysiol* 75:454–468.
- Talairach J, Tournoux P (1988): *Co-planar stereotaxic atlas of the human brain: A 3-dimensional proportional system, an approach to cerebral imaging*. New York: Thieme Medical Publishers.
- Tehovnik EJ, Sommer MA, Chou IH, Slocum WM, Schiller PH (2000): Eye fields in the frontal lobes of primates. *Brain Res Brain Res Rev* 32:413–448.